MANIPAL INSTITUTE OF TECHNOLOGY
MANIPAL
(A constituent unit of MAHE, Manipal)

BME 4408 – Medical Imaging

Course Project

Brain MRI Tumour Segmentation and Subregion Analysis

Submitted By

Indira H S (220902006)

Shaivi R Panchal (220902016)

Reva Laghate (220902020)

Sneha Sarkar (220902026)

Tejasvee Singh (220902036)

Date of Submission: 23rd July 2025

CHAPTER 1

INTRODUCTION

1.1 Overview

This project focuses on Brain MRI Tumour Segmentation and Subregion Analysis, specifically targeting the automated segmentation and characterisation of gliomas using multi-sequence magnetic resonance imaging (MRI). The primary objective is to develop a robust image analysis pipeline capable of accurately identifying and delineating clinically relevant tumour subregions, including the enhancing tumour, tumour core, and peritumoral oedema regions.

A. Imaging Modality and Dataset

The imaging modality employed in this project is Magnetic Resonance Imaging (MRI), utilising multi-sequence brain scans that typically include:

- T1-weighted imaging: Provides structural anatomy visualization
- T2-weighted imaging: Highlights oedema and fluid content
- FLAIR (Fluid-Attenuated Inversion Recovery): Suppresses cerebrospinal fluid signals for enhanced lesion visibility
- Post-contrast T1-weighted imaging: Reveals enhancing tumour regions

B. Dataset

Pre-operative_TCGA_LGG_NIfTI_and_Segmentations
The Cancer Genome Atlas – Low Grade Glioma contains scans (T1, T1-Gd, T2, T2-FLAIR) that are skull-stripped. The TCIA Data Usage Policy and Restrictions were followed. Attribution includes the citation, including the Digital Object Identifier:

Bakas S, Akbari H, Sotiras A, Bilello M, Rozycki M, Kirby J, Freymann J, Farahani K, Davatzikos C. (2017) Segmentation Labels and Radiomic Features for the Pre-operative Scans of the TCGA-LGG collection [Data Set]. The Cancer Imaging Archive. DOI: 10.7937/K9/TCIA.2017.GJQ7R0EF

C. File Format

The dataset is stored in NIfTI (Neuroimaging Informatics Technology Initiative) format, which provides a standardised structure for neuroimaging (MRI and fMRI) data storage and exchange. NIfTI files typically contain the entire 3D image volume in a single compressed file (.nii.gz), along with essential header information including voxel dimensions, spatial orientation, affine transformations and transformation matrices. This makes it possible to map voxel data to real-world coordinates while preserving image orientation. In Python, libraries like Nibabel allow loading (nib.load()), converting to arrays (.get_fdata()), and accessing header information for analysis and visualisation.

D. Clinical Motivation

Gliomas represent the most common primary brain tumours in adults, accounting for approximately 80% of all malignant brain tumours. These tumours arise from glial cells and exhibit significant heterogeneity in their biological behaviour, growth patterns, and response to treatment. Accurate segmentation and characterisation of glioma subregions is crucial for several clinical applications:

1. Treatment Planning: Precise tumour boundary delineation enables optimal surgical resection planning, ensuring maximum tumour removal while preserving critical brain functions.
2. Radiation Therapy: Accurate segmentation guides targeted radiation delivery, minimising exposure to healthy brain tissue while ensuring adequate coverage of tumour regions.
3. Prognosis Assessment: Quantitative analysis of tumour characteristics, including volume, shape, and heterogeneity, provides valuable prognostic indicators for patient outcomes.
4. Treatment Monitoring: Longitudinal assessment of tumour response to therapy requires consistent and reproducible segmentation methods.

E. Importance in Real-World Healthcare

The automated segmentation of brain tumours addresses several critical challenges in contemporary healthcare:

1. Clinical Workflow Efficiency: Manual tumour segmentation by radiologists is time-consuming, taking 1-4 hours per case, and subject to inter-observer. Automated methods can significantly reduce processing time while maintaining or improving accuracy.
2. Standardisation: Automated approaches provide consistent, reproducible results across different institutions and practitioners, reducing subjective interpretation variability that can impact treatment decisions.
3. Precision Medicine: Detailed quantitative analysis of tumour characteristics enables personalised treatment strategies based on individual tumour profiles, moving beyond traditional one-size-fits-all approaches.
4. Resource Optimisation: In resource-limited settings, automated tools can provide expert-level analysis where specialized radiologists may not be readily available, improving global healthcare accessibility.

F. Disease Description and Imaging Support

Gliomas are infiltrative tumours that invade surrounding brain tissue rather than forming discrete masses. They are classified into different grades (I-IV) based on their histological features, with Grade IV glioblastoma being the most aggressive.

Each MRI sequence provides complementary information essential for comprehensive tumour assessment:

- T1-weighted pre-contrast: Provides baseline anatomical reference and helps identify necrotic regions
- T2-weighted and FLAIR: Delineates the full extent of tumour infiltration, including non-enhancing components and surrounding oedema
- T1-weighted post-contrast: Identifies blood-brain barrier breakdown, revealing active tumour regions with contrast enhancement

The project targets three clinically significant subregions:

1. Enhancing Tumour (ET): Active tumour tissue with blood-brain barrier disruption
2. Tumour Core (TC): A combination of enhancing tumour and necrotic regions
3. Whole Tumour (WT): Complete tumour extent including surrounding oedema

G. Main Challenges

1. Image Quality Variability: MRI scans exhibit significant variability due to different scanner manufacturers, field strengths, acquisition protocols, and patient-specific factors, requiring robust preprocessing and normalisation strategies.
2. Tumour Heterogeneity: Gliomas display substantial intra- and inter-tumour heterogeneity in terms of intensity patterns, morphology, and enhancement characteristics, making automated segmentation challenging.
3. Boundary Definition: Tumour boundaries, particularly for infiltrative components, are often poorly defined with gradual transitions to normal tissue, creating ambiguity in ground truth annotations.
4. Class Imbalance: Tumour regions typically occupy a small fraction of the total brain volume, creating significant class imbalance that can bias automated algorithms toward over-segmenting normal tissue.
5. Multi-Modal Integration: Effectively combining information from multiple MRI sequences.

1.2 Pipeline for Data Acquisition

Steps	Task	Details
1	Import Libraries	nibabel, numpy, matplotlib
2	Load NIfTI image	nib.load(0), .nii.gz
3	Convert to NumPy array	get_fdata()
4	Basic visualization	Showed middle slice and multiple slices
5	Orthogonal views	Visualized axial, coronal, saggital
6	Metadata inspection	Shape, voxel, dimensions, datatype, affine, description
7	Voxel intensity analysis	Printed min, max, mean, std value
8	Histogram plotting	Histogram of voxel intensity distribution

1.3 Data Visualisation

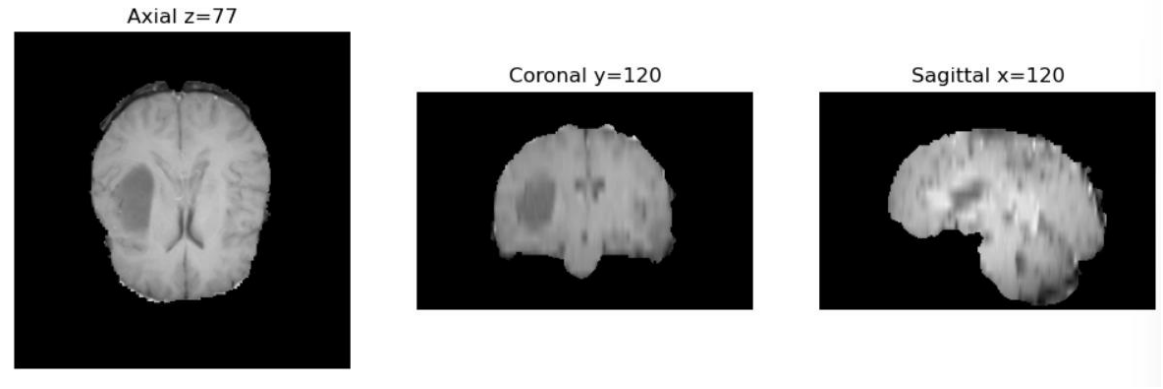

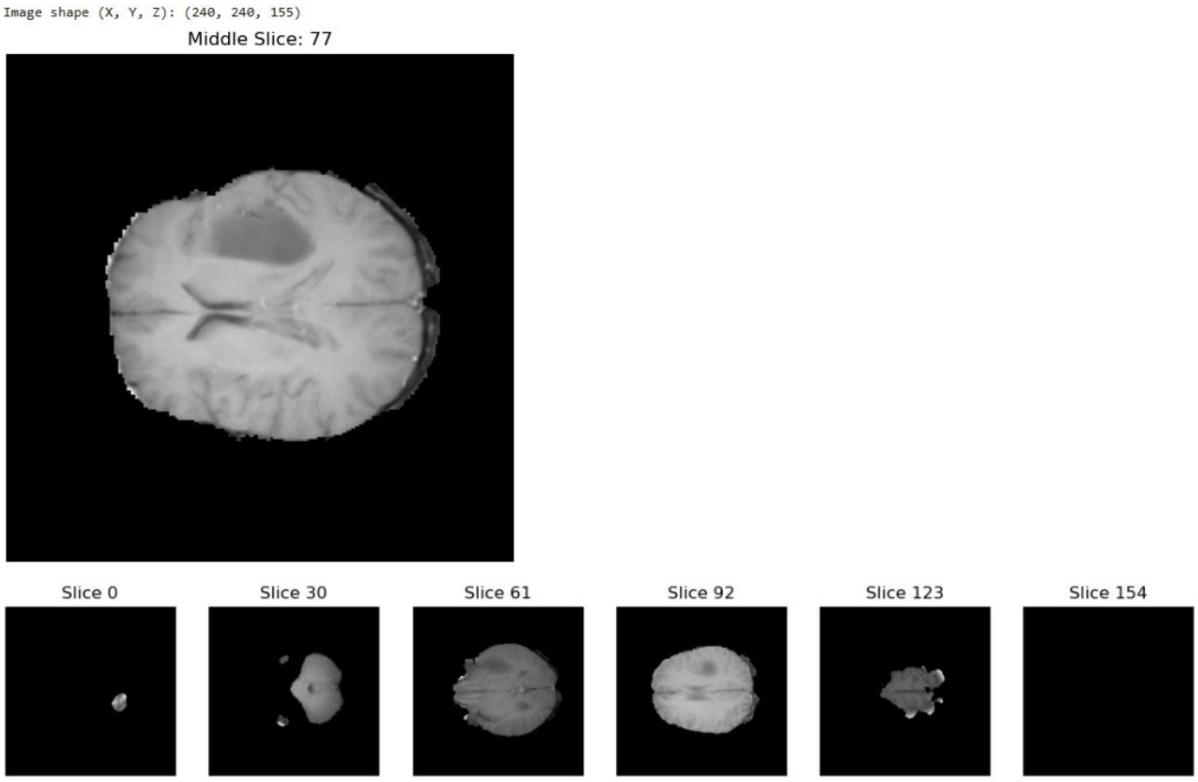

<u>Observations:</u>

Axial (z=77): Horizontal slice, looking from above. You can clearly see brain structures like ventricles and cortical tissue.

Coronal (y=120): Vertical slice, front-to-back. This is like looking at the face. The darker regions could be ventricles or lesions.

Sagittal (x=120): Vertical slice, side view (cut between left and right hemispheres).

So, our image is a structural brain MRI (T1-weighted), with grey/white matter contrast visible.

<u>Dimensions</u>: chosen slice indices (z=77, y=120, x=120) are in the middle of the dataset, the full volume is at least ~150–200 voxels in each dimension.

The brightness/contrast seen is just raw intensity. The “fuzzy” look (especially sagittal/coronal) may be due to voxel anisotropy (e.g. slices are thicker than in-plane resolution) or display interpolation.

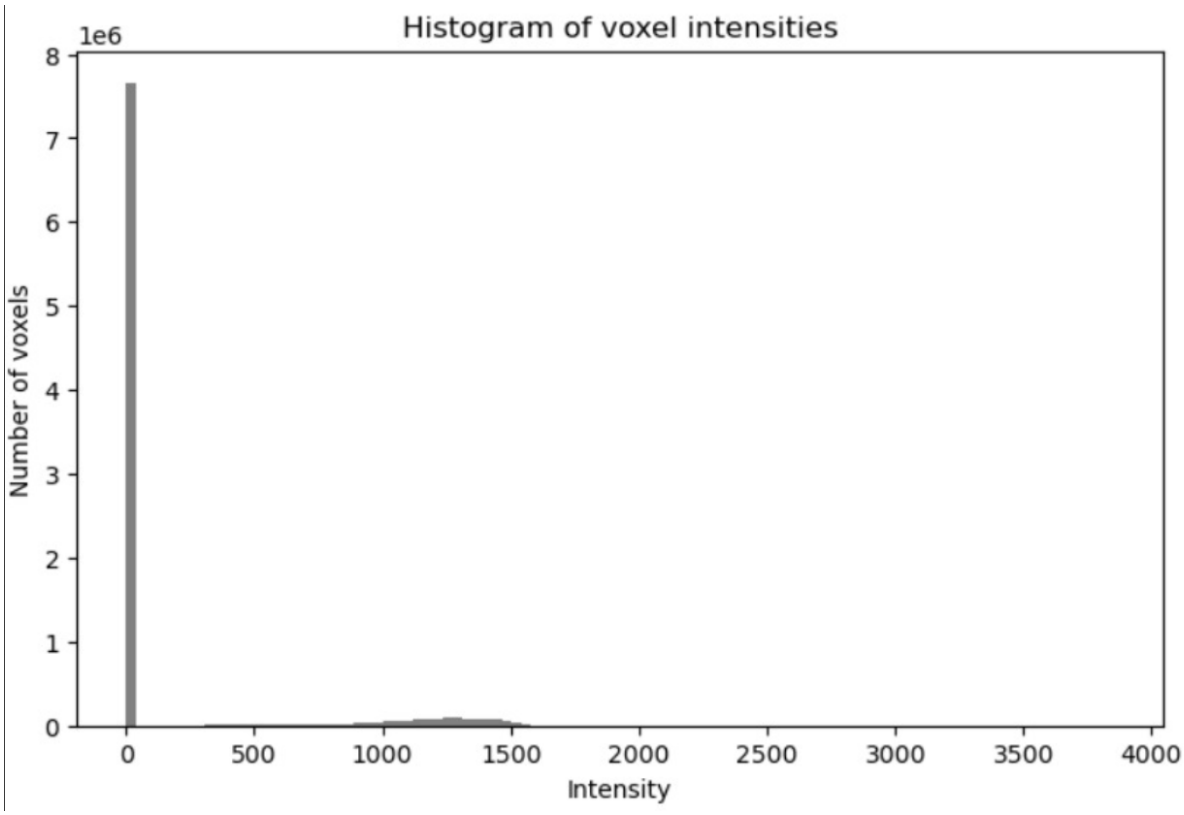

Histogram:

A huge spike near 0 corresponds to background voxels (air/outside the brain).

In MRI scans, most of the 3D volume is just background, which explains why the majority of voxel values are zero or close to zero. A smaller spread between ~500–1500 represents actual brain tissues (gray matter, white matter, CSF, tumour, etc.).

Nifti Metadata:

Category	Examples of Information Stored	Importance
File Extension	.nii.gz	Defines how the file is stored on disk (compressed).
Image Dimensions	(240 × 240 × 155 voxels)	Defines size of the 3D image volume.
Voxel Size	(1.0 mm × 1.0 mm × 1.0 mm)	Ensures measurements are in correct physical units.

Affine Matrix	\[−1,0,0,−0],[0,−1,0,239],[0,0,1,0],[0,0,0,1]\[-1, 0, 0, -0], [0, -1, 0, 239], [0, 0, 1, 0], [0, 0, 0, 1]	Maps voxel coordinates to real-world (patient) coordinates.
Data Type	int16	Defines precision of stored voxel values.
Multi-Channel/Time	Dimension field shows only 3D (no time series).	The dataset is a single 3D structural scan.
Header Info	qform/sform codes, scaling factors, voxel order, intent codes, description	Guides how the image should be correctly interpreted and spatially oriented.
Intensity Stats	Range: 0 – 3853; Mean: 164.37; Std: 417.40	Useful for preprocessing and normalization

References:

1. Bakas S, Akbari H, Sotiras A, Bilello M, Rozycki M, Kirby J, Freymann J, Farahani K, Davatzikos C. (2017) **Segmentation Labels and Radiomic Features for the Pre-operative Scans of the TCGA-LGG collection** [Data Set]. The Cancer Imaging Archive.